

## Cost Effective Tissue Expander for Post Burn Neck Contracture

**Kumaran S.\*, Chittoria R. K.\*\*\*, Pandey S.\*, Bibilash B. S.\*, Friji M. T.\*\*\*, Mohapatra D. P.\*\*\*, Dinesh S. K.\*\*\***

\*Senior Resident \*\*Head \*\*\*Associate Professor, Department of Plastic Surgery, JIPMER, Pondicherry, India.

---

### Abstract

Traditionally used tissue expander is costly and needs a large incision and major procedure for its insertion. Incision used for expander insertion can jeopardize the vascularity near the wound, gives a cosmetically unacceptable larger scar and also can make the site unsuitable for use as a flap. This article presents use of Foley's catheter with inflatable bulb tissue expansion to facilitate the primary closure of wound in a case of post burn contracture.

**Keywords:** Tissue Expansion; Foley's Catheter; Post Burn Contracture.

### Introduction

Tissue expansion is a procedure in which the body is stimulated to generate extra soft tissue by the application of stretching forces which, over a period of time, results in expansion of the tissue. Several types of tissue expanders exist, based on shape, size, surface, type of filling valve, number of filling valve etc. Expanders can be standard, customized, anatomic to the site (e.g. breast expander), differential in fill volume to provide tapering of tissue. Tissue expansion is becoming highly useful method in plastic surgery in various surgeries at different sites. Tissue expander if used at suitable site, in a timely manner and in a planned way can significantly improve the outcome of definitive surgery as it facilitates primary closure or reduces the defect size to the extent where requirement of cover (skin graft/ flap) becomes lesser in size.

Genesis of modern day tissue expansion is credited to Radovan and Austad. However First tissue expansion was reported by Codvilla, 1905 for elongation of femur by traction. Despite these early efforts, it was not until 20 years after Neumann's report that tissue expansion was revisited. Neumann of New York, 1950 was the first surgeon to use tissue expander for soft tissue. Various innovations has been done in the field of tissue expansion and self inflating device was discovered by Eric Austad, 1982 [1,2,3]. In 1982, the first National Tissue Expansion Symposium was sponsored by Plastic Surgery Educational Foundation (PSEF), marking the recognition of a new advance and field in reconstructive surgery.

Since that time expansion has been applied to a multitude of reconstructive problems with applications demonstrated in both regional expansion and expansion at distant sites for subsequent graft and flap transfer. Better understanding of expansion has allowed many modifications in flap design, increasing its worth as a reconstructive option [4].

There have been several more technically advanced tissue expanders that have been developed, such as osmotic-gradient-driven self-expanding devices [5]. Conventionally, a neck contracture is treated by release of contracture and cover by skin graft or flap cover. When contracture is mild in nature with band like contracture then Z-Plasty can be used to close the wound after release of contracture but due to contracted tissue and unavailability of laxated surrounding tissue Z-plasty may become difficult to execute. Expansion of tissue around the contracted band may help in facilitating in doing Z-plasty. Conventional expanders are costly and may not be available. Foley's catheter with expandable balloon may be used as a safe alternative for tissue expansion.

---

**Corresponding Author: Ravi Kumar Chittoria**, Head, Department of Plastic Surgery, JIPMER Pondicherry – 605006, India.

Email: [drchittoria@yahoo.com](mailto:drchittoria@yahoo.com)

## Methodology

The present study was conducted in the Department of Plastic Surgery, JIPMER, Pondicherry. Detailed history and examination was recorded. Investigations were done to rule out systemic diseases and for anesthesia fitness. Underlying co morbidities (anemia, hypoproteinemia, infection) were controlled before reconstruction. 16 Fr Foley's catheter was inserted as an expander inside the healthy skin around the wound under local anesthesia under all aseptic precautions (figure 1). The Foley's catheter was inserted by making a separate incision of 0.5 to 1 cm away from the propose incision. Foley's catheter was inserted by making tunnel under the skin using artery forceps. After insertion of Foley's catheter the bulb was kept near the wound margin. Port site was sutured and catheter was fixed with suture.

Two Foley's catheters were required. The bulb of the Foley's catheter was started inflating immediately on the day of insertion. 0.5 cc to 1 cc of distilled water was used to inflate the bulb daily or alternate day, depending upon the patient's tolerance to the tissue expansion. The process of expansion of bulb was continued till the desired expansion was achieved

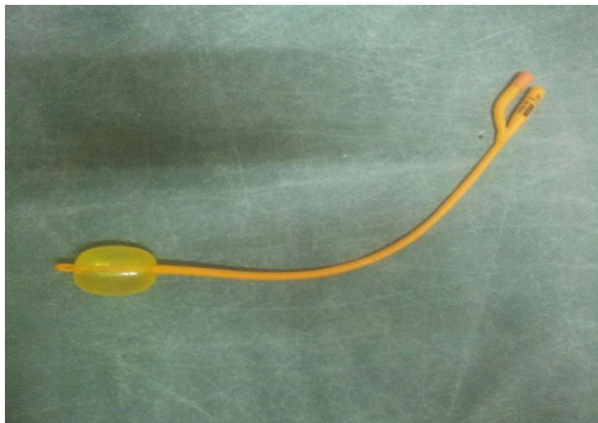or the capacity of the bulb (50 cc) achieved. On the Day of reconstruction, Foley's catheter was removed and contracture release was done and primary closure was achieved without tension over suture line.

## Case Summary

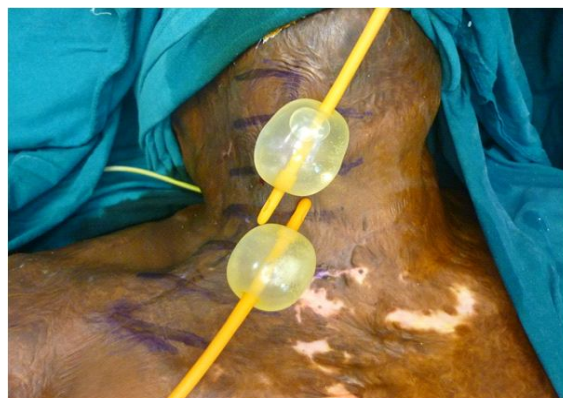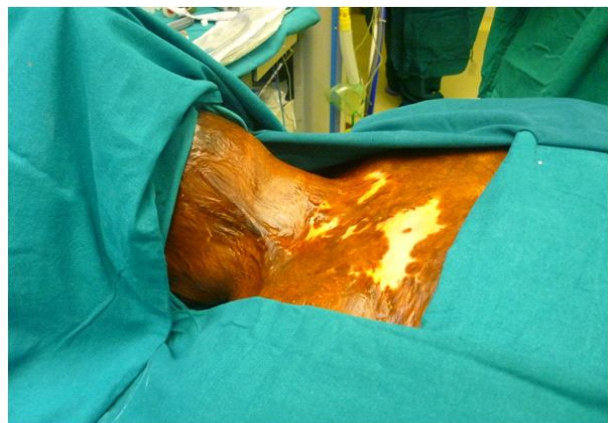A 30 year old lady with alleged history of thermal burn 7 month back, presented to the outpatient department with inability to extend the neck. Detailed history and examination was performed. A contracture band was found at the flexor aspect of neck extending from base of the neck to the mandible measuring of 15 x5 cm. Surrounding skin was found to be scarred with reduced laxity. Patient was investigated and pre anesthetic work up was done. First surgery was done under local anesthesia and two Foley's catheters were introduced. Port site was closed and catheter was fixed.

Serial expansion of bulb was started daily by using 0.5 to 1 cc of distilled water which was increased later depending on patient's tolerance to pain. Total 50- 70 ml of distilled water was used in both catheters. At the end of expansion sessions patient was posted for definitive surgery. Contracture

**Fig. 1:** Foley's catheter which was used as an expander

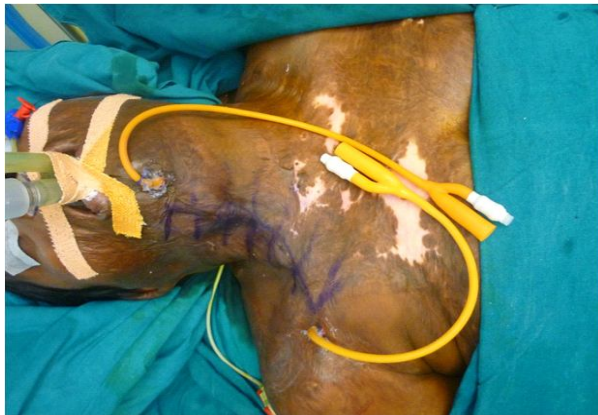

**Fig. 2:** Pre operative photo of scar

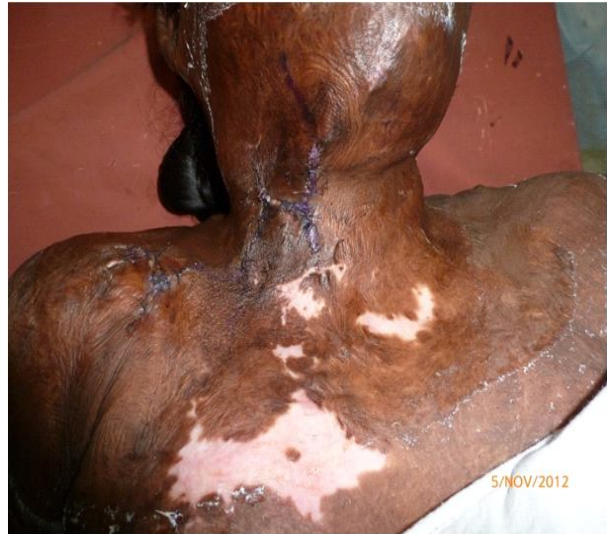

**Fig. 3:** Showing Foley's catheter with inflated bulb

**Fig. 4:** Patient with proposed incision and Foley's catheter in situ

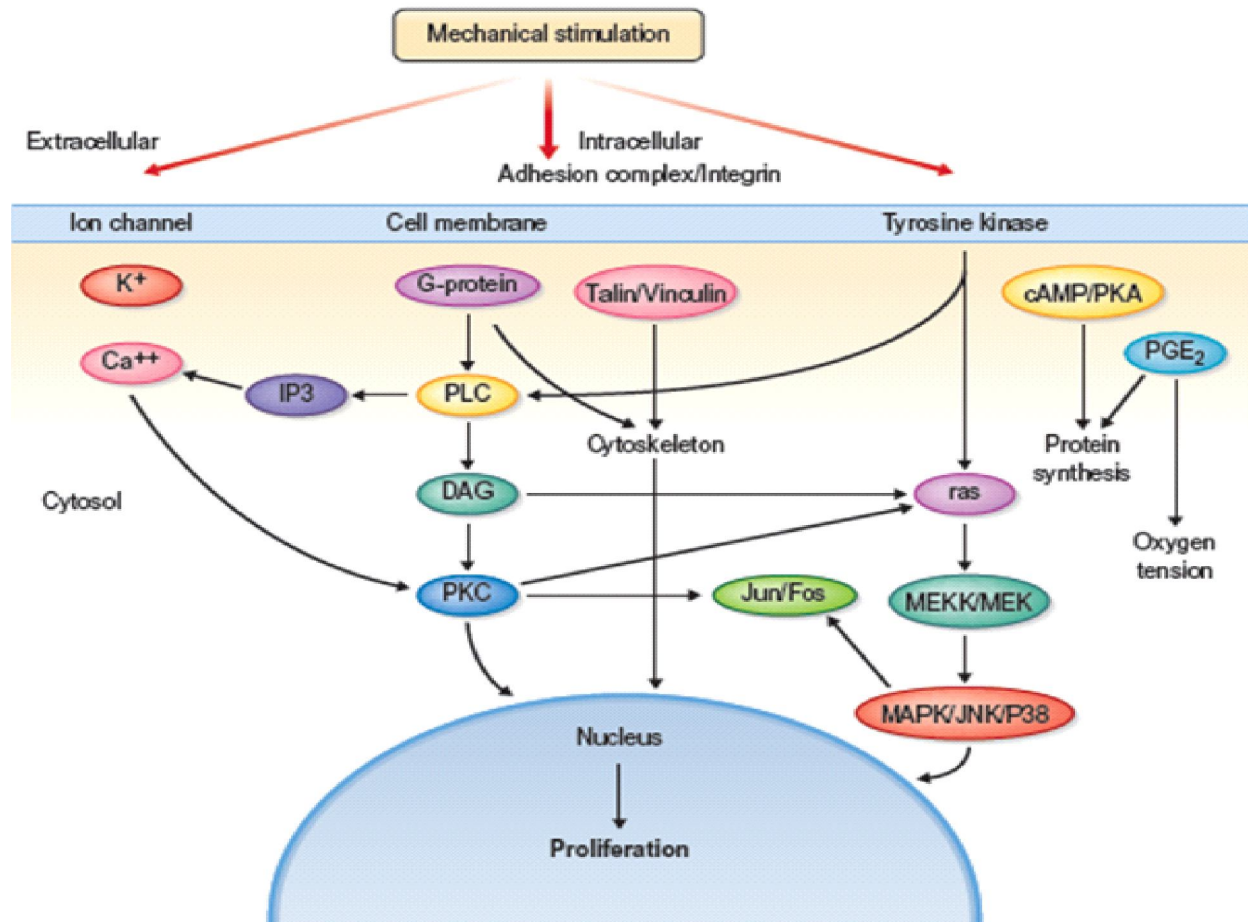


**Fig. 5:** Post operative photo showing all flaps closed primarily



released was one by multiple Z- Pasty technique and closure of all flaps was achieved without tension. Postoperatively patient was managed with antibiotics, analgesics and other symptomatic drugs. Sutures were removed after 10 days. Wound healed adequately and no wound dehiscence was noticed.

**Fig. 6:** Showing cellular and molecular basis of tissue expansion



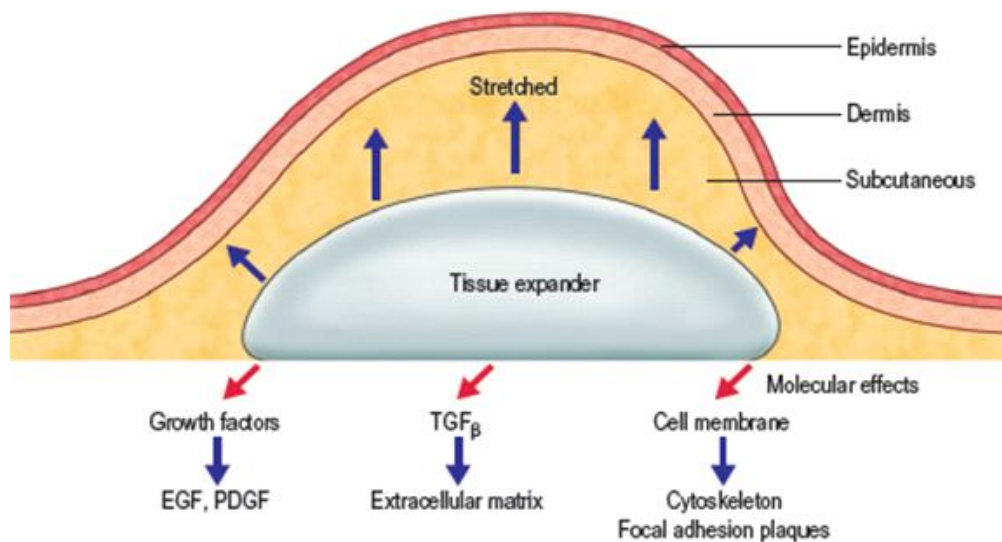
## Discussion

Creep is the basic phenomenon responsible for tissue expansion. Creep is the tendency of a solid material to move slowly or deform under the influence of mechanical stress. Creep can be of two types - Mechanical creep and Biological creep. Tissue expansion is a reliable method of providing additional cutaneous tissue; thereby optimizing contour and color match in given reconstructive effort (figure 6) [6].

Various effects of tissue expansion are as follows-

- Increased Surface area
- Thickening of Epidermis
- Thinning of Dermis
- Alignment of Collagen fibrils
- Improved vascularity
- Elongation of Nerves
- Elongation of Bone

**Fig. 7:** Showing effects of tissue expansion on surrounding tissue



- Capsule formation (figure 7).

This enhanced vascularity and compensatory increased circulation has been shown to improve random-pattern flap survival compared with control skin [6]. However, after removal of the expander, the

epidermal thickness gradually returns back to normal after 4–6 weeks. The pilosebaceous elements are well preserved, although they may be compressed on histological examination. Hyper pigmentation is noticeable because of hyperactivity of melanocytes

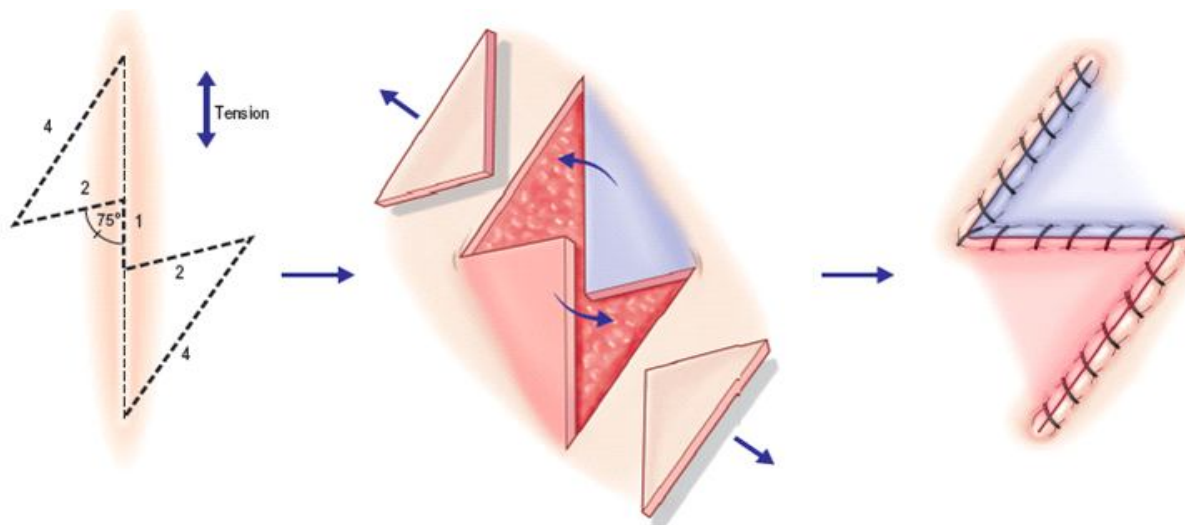
**Fig. 8:** Commonly used expanders available



during expansion, however, it returns back to normal slowly after removal of the expander [7].

The shapes of the expanders are of three types: round, rectangular, and crescent etc. Expander volumes have a wide range and vary according to the anatomic site. Saline is delivered in a controlled fashion via the valve port, which is either integrated into the prosthesis or connected to the device by silicone tubing of customized length (figure 8). The present study highlights the cost effective method of tissue expansion in wound management.

**Fig. 9:** Planning and principles of Z-plasty



wound closure etc. are the necessary and challenging steps for the surgeon.

Port related problems especially port displacement is of great concern in conventional expander.

Z-plasty refers to transposition of two triangular flaps, usually of equal size and equal angle, into each other's defect. Planning and performing Z-plasty requires an understanding of geometric principles. Laxity of surrounding tissue is used to incorporate into the contracted area (figure 9).

We used Foley's catheter as an alternative of conventional tissue expander. Various advantages of Foley's catheter over conventional expander can be summarized as follows:

- Available in small sizes
- Cost effective
- Easily available
- Requires small incision for placement
- Easy placement by subcutaneous tunneling method

When a constant mechanical stress is applied to skin over time, two phenomena occur: mechanical creep and biological creep. Mechanical creep is based on morphologic changes that occur on a cellular level in response to the applied stress—the cell is stretched. Disruption of gap junctions and increased tissue surface area result in cell proliferation (biologic creep).

During placement of conventional tissue expander proper Infiltration, planned incision, careful raising of flap, minimum handling of device, Hemostasis, Pocket irrigation, tubing and port placement, perfect

Maintain integrity of local tissue to be used as a flap

Minimum dissection

Minimum chances of seroma and infection

### Conclusion

Based on our case Foley's catheter bulb could be used as a safe, simple and cost effective alternative of low volume tissue expanders. Especially in certain circumstances like Unavailability of small expanders and Unaffordability by the patient.

### References

1. Neumann C G. The expansion of an area of skin by progressive distention of a subcutaneous balloon; use of the method for securing skin for subtotal reconstruction of the ear. *Plast Reconstr Surg.* 1957; 19:124–130.

2. Bruce S. Bauer. Tissue Expansion. In: *Grabb and Smith's Plastic Surgery*. Charles H. Thorne. 6<sup>th</sup> ed, 2007; chapter 10; 84-90.
3. Neumann CG. The expansion of an area of skin by progressive distention of a subcutaneous balloon. *Plast Reconstr Surg*. 1957; 19:124.
4. Bauer BS, Margulis A. The expanded transposition flap: shifting paradigms based on experience gained from two decades of pediatric tissue expansion. *Plast Reconstr Surg*. 2004; 114:98-106.
5. Austad E D, Rose G L. A self-inflating tissue expander. *Plast Reconstr Surg*. 1982; 70: 588-594.
6. Rappard J H van, Molenaar J, Doorn K van, Sonneveld G J, Borghouts J M. Surface-area increase in tissue expansion. *Plast Reconstr Surg*. 1988; 82: 833-839.
7. Pasyk KA, Argenta LC, Hassett C. Quantitative analysis of the thickness of human skin and subcutaneous tissue following controlled expansion with a silicone implant. *Plast Reconstr Surg*. 1988; 81: 516-23.
8. Peter Lorenz and A. Sina Bari ; *Neligan plastic surgery*; volume 1; chapter 16; page 298-318.

## Instructions to Authors

Submission to the journal must comply with the Guidelines for Authors.  
Non-compliant submission will be returned to the author for correction.

To access the online submission system and for the most up-to-date version of the Guide for Authors please visit:

<http://www.rfppl.co.in>

Technical problems or general questions on publishing with NIJS are supported by Red Flower Publication Pvt. Ltd's Author Support team (<http://www.rfppl.co.in>)

Alternatively, please contact the Journal's Editorial Office for further assistance.

A Lal  
Publication-in-Charge  
New Indian Journal of Surgery  
Red Flower Publication Pvt. Ltd.  
48/41-42, DSIDC, Pocket-II  
Mayur Vihar Phase-I  
Delhi – 110 091  
India

Phone: 91-11-22754205, 45796900, Fax: 91-11-22754205

E-mail: [redflowerppl@gmail.com](mailto:redflowerppl@gmail.com), [redflowerppl@vsnl.net](mailto:redflowerppl@vsnl.net)